

## CR#25

### **Pediatric Airtraq® in a patient with Treacher Collins syndrome**

Paediatric Anaesthesia 19,908-928

Y. Hirabayashi, N. Seo. Jichi Medical University. Japan

A 9-year-old girl with mental retardation, weighing 23 kg, was scheduled for surgical repair of atresia auris congenita

Direct laryngoscopy using the **Macintosh laryngoscope revealed the tip of the epiglottis but not glottic opening** (Figure 1a). An anesthesia resident inserted the pediatric AOL into the mouth and very easily captured the **full view of the vocal cords** (Figure 1b). **An endotracheal tube with cuff (internal diameter of 5.0 mm) was intubated within 40 s,**

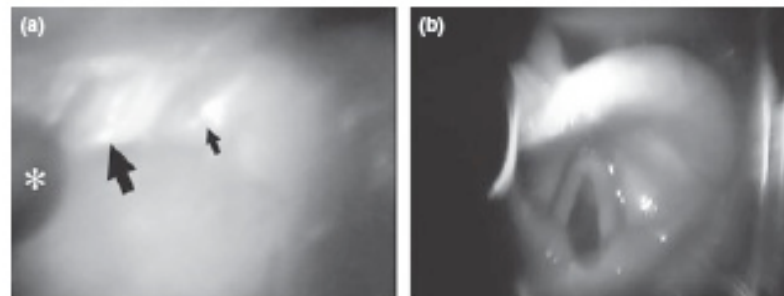


Figure 1 (a) Image taken during Macintosh laryngoscopy. Macintosh blade; thick arrow, epiglottis; thin arrow, arytenoids. Note: This image was captured by a CCD camera positioned at the right side space in the oral cavity, and thereby the image was different from the actual direct view of the laryngoscopist who could find the tip of the epiglottis only. (b) Glottic exposure using the pediatric Airtraq® optical laryngoscope handled by an anesthesia resident, who performed successful tracheal intubation within 40 s.